Malignant Bone Tumors - Part I: a brief revision of diagnostic aspects with conventional radiology

Poster No.: C-2473

Congress: ECR 2013

Type: Educational Exhibit

Authors: I. Candelaria, L. B. Barbosa, S. P. F. P. Basso, M. J. Noruegas, P. J. V. Coelho, A. Estevao; Coimbra/PT

Keywords: Neoplasia, Diagnostic procedure, Conventional radiography, Musculoskeletal bone

DOI: 10.1594/ecr2013/C-2473

Learning objectives

- Provide an insight of the diagnostic approach of malignant bone tumors, with conventional radiography
- Review some of the most important imaging findings of malignant bone tumors
- Provide a simplified diagnostic approach of malignant bone tumors, regarding age group, location and morphology of the lesions

Background

#The use of conventional radiology in the detection of bone tumors, whether malignant or benign, is fundamental. This modality yields the most useful information about location and morphology of bone lesions.

#MALIGNANT BONE TUMORS

- Often present with nonspecific symptoms
- Incidental finding on standard radiographs
- Important to recognize signs of an aggressive lesion: early diagnosis and prompt treatment improve outcome
- Once a malignant tumor is detected, further diagnostic workup is required to better characterize the lesion

<u>What should the imaging strategy be?</u>

The following diagram illustrates a diagnostic approach for malignant bone tumors (Fig. 1 on page 12).

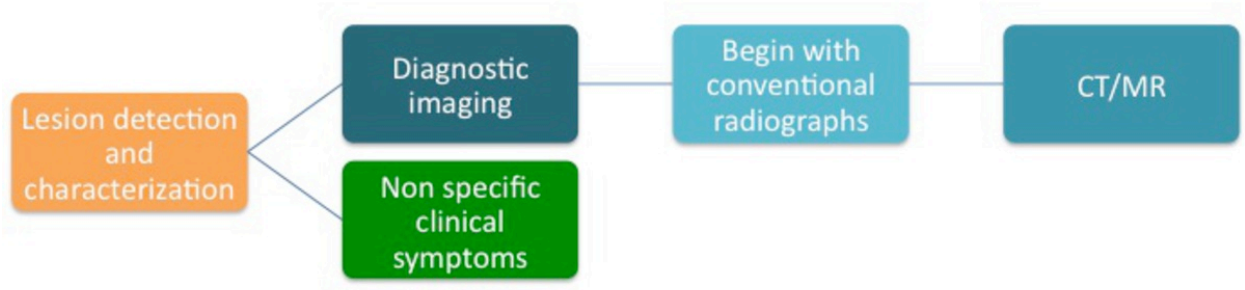

Fig. 1: Diagnostic approach of malignant bone tumors
References: Radiology, Centro Hospitalar e Universitario de Coimbra, Hospital Geral - Coimbra/PT

Fig. 2: Schematic features of aggressive lesions.
References: Radiology, Centro Hospitalar e Universitario de Coimbra, Hospital Geral - Coimbra/PT

Fig. 3: Schematic features of non aggressive lesions.
References: Radiology, Centro Hospitalar e Universitario de Coimbra, Hospital Geral - Coimbra/PT

#***CONVENTIONAL RADIOGRAPHY***

Conventional radiographs play an important role in the diagnosis of malignant bone tumors, allowing:

- Lesion detection
- Comparison with previous exams. This helps to understand the nature of the lesion and also its aggressiveness.
- Demonstrates key aspects in lesion characterization: patients **age**, **site and borders of the lesion**, **multiplicity**, **bone matrix**, **type of bone destruction** and **periosteal response**, as well as associated **soft tissue mass**.

Age

Without any doubt, this is the most important part of the clinical data which aids in the radiographic diagnosis of a tumor. One must keep in mind that certain tumors demonstrate predilection for specific age groups. The following figure illustrates tumor distribution according with age group.

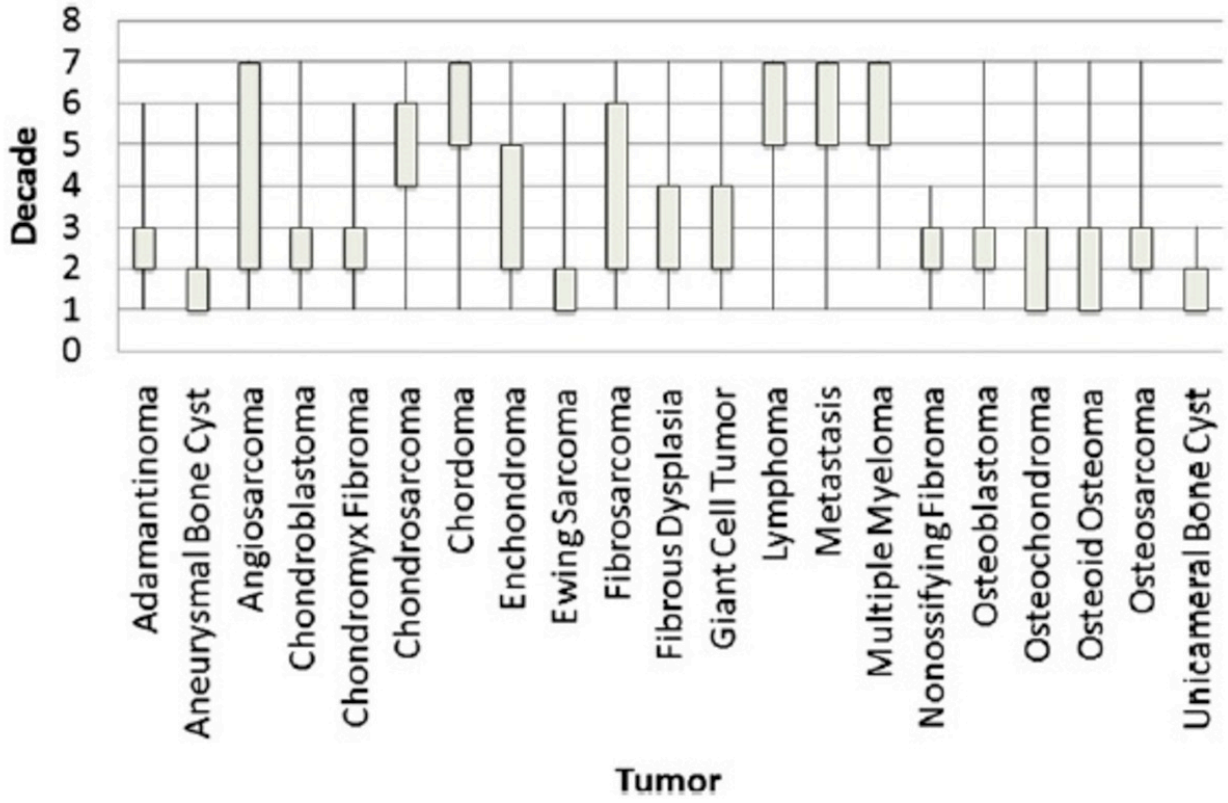

Fig. 4: Tumor distribution based on age group
References: Nichols et al (2011) Radiographic analysis of solitary bone lesions, Radiol Clin Am, 49, 1095-1116

Site of Lesion

Fundamental in tumor diagnosis. Some tumors show predilection for a specific bone or site, sometimes allowing a prompt diagnosis based only on this characteristic.

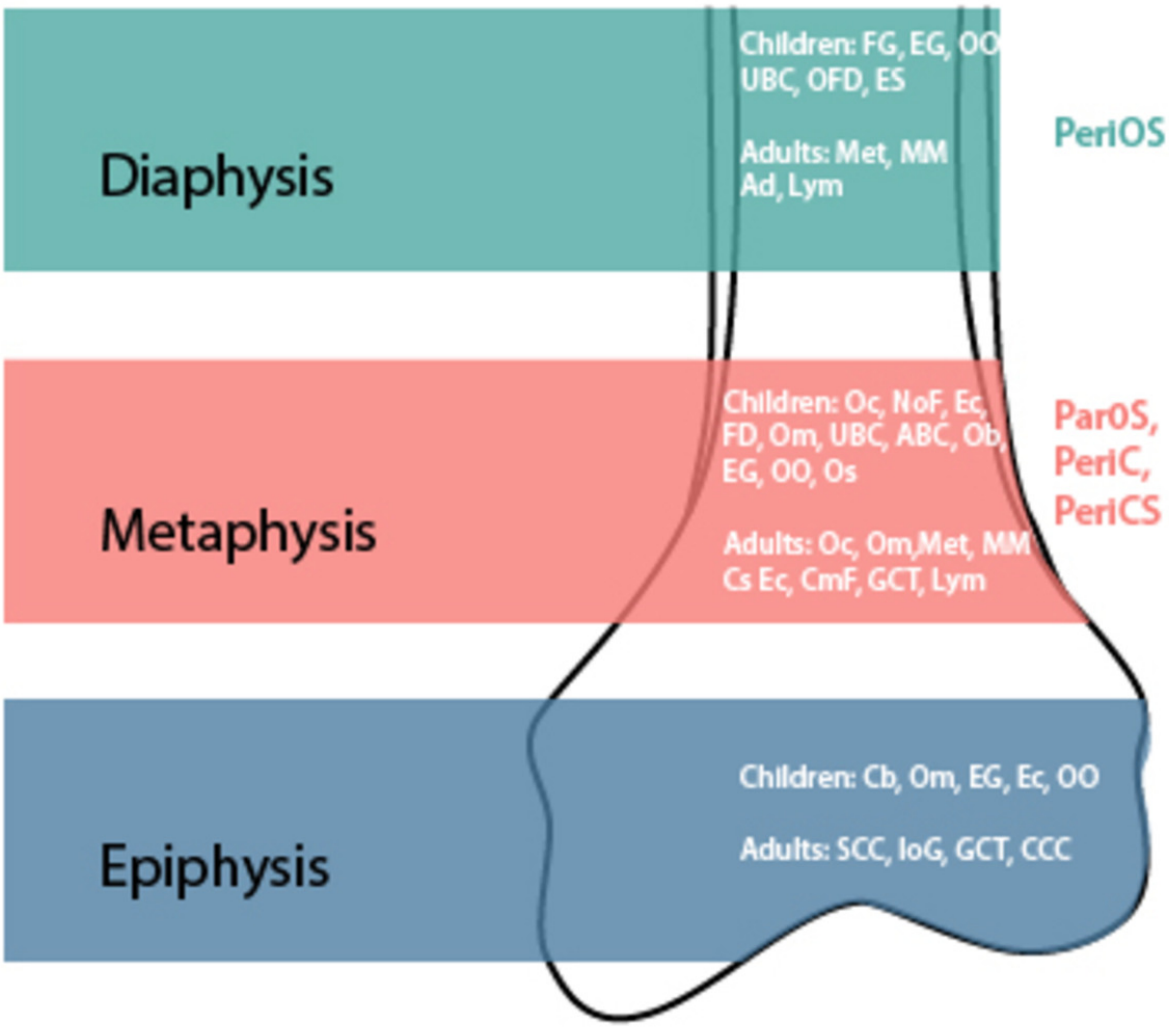

Fig. 5: Schematic representation of tumor distribution in the bone, in children and adults. ABC - aneurismal bone cyst; Ad, adamantinoma; Cb, chondroblastoma; CCC, clear cell chondrosarcoma;CmF, chondromyxoid fibroma; Cs, chondrosarcoma; Ec, enchondroma; EG, eosinophilic granuloma; ES, Ewing sarcoma; FD, fibrous dysplasia;GCT, giant cell tumor; IoG, intraosseous ganglion; Lym, lymphoma; Met, metastasis; MM, multiple myeloma; NoF, nonossifying fibroma; Ob, osteoblastoma; Oc, osteochondroma; OFD, osteofibrous dysplasia; Om,osteomyelitis; OO, osteoid osteoma; Os, osteosarcoma; ParOS, parosteal osteosarcoma; PeriC, periosteal chondroma; PeriCS, periosteal chondrosarcoma; PeriOS, periosteal osteosarcoma; SCC, subchondral cyst;UBC,unicameral bone cyst.
References: Radiology, Centro Hospitalar e Universitario de Coimbra, Hospital Geral - Coimbra/PT

Multiplicity

When examining a radiograph, the presence of multiple lesions usually indicates metastatic disease, multiple myeloma or lymphoma. Only rarely do primary malignant lesions present in this way.

Bone Matrix

Represents the components that bone tumors are composed of. Usually, only osteoblastic and cartilaginous tissue can be cleary demonstrated on conventional radiographs.

The presence of bone within or adjacent to a lesion can be related to the presence of an osteosarcoma or can be the result of a reparative process. "Fluffly" or "cotton-like" calcifications should suggest tumorous bone.

Cartilage is usually associated with "popcorn-like", punctate, annular or comma-like calcifications.

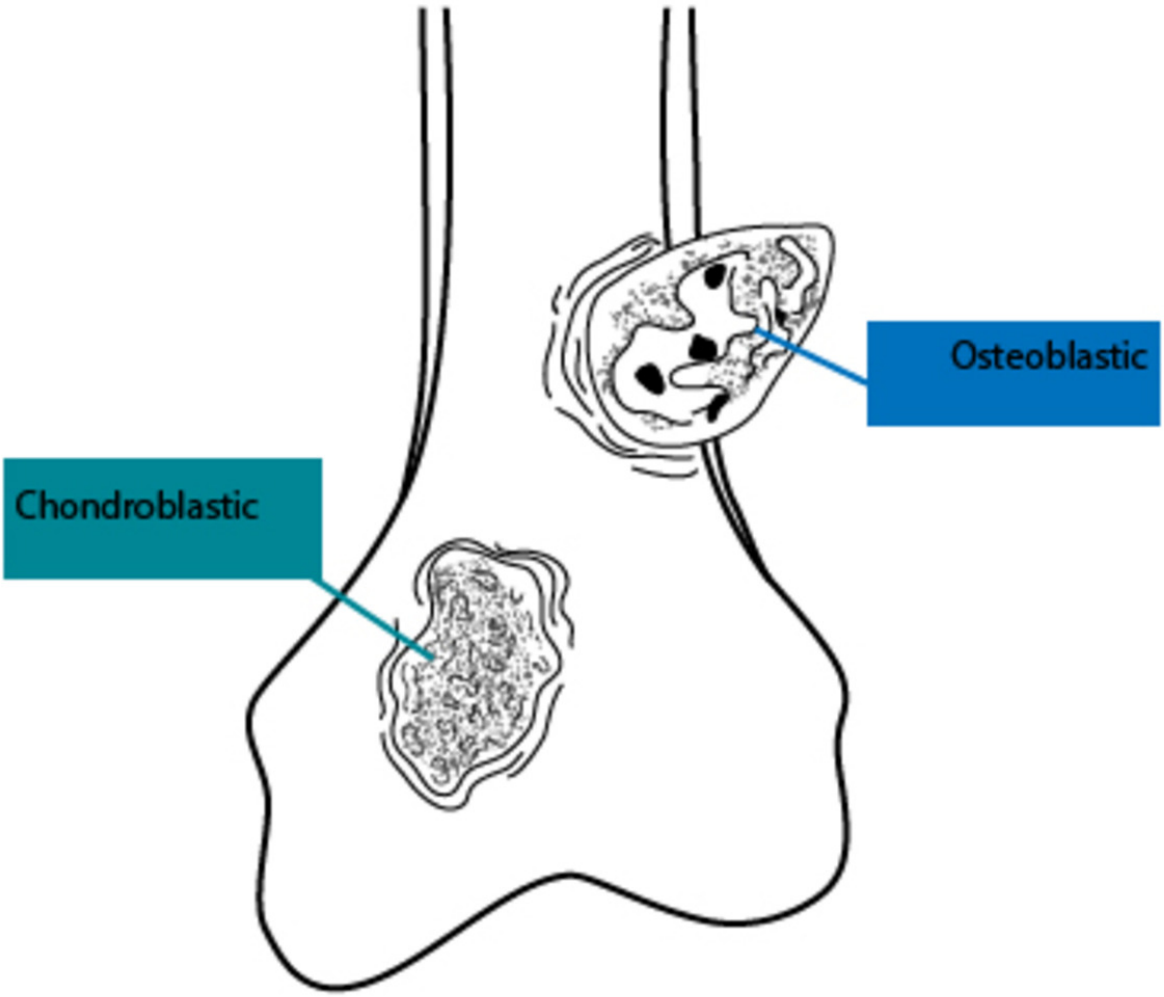

Fig. 6: Schematic representation of tumorous bone matrix.
References: Radiology, Centro Hospitalar e Universitario de Coimbra, Hospital Geral - Coimbra/PT

Borders and type of bone destruction

Evaluation of the borders or margins of bone lesions is fundamental in determining if it's a slow growing or fast growing lesion. There are essentially three types of bone margins, as exemplified in Fig. 7 on page 13 . As a general "rule", slow growing lesions are usually benign, with sclerotic borders. On the other hand, malignant (or aggressive) lesions typically have indistinct borders and may show rapid growth.

The type of bone destruction is usually linked to growth rate of the tumor. Fig. 7 on page 13 also illustrates the type of bone destruction that can be seen (moth-eaten, permeative and geographic).

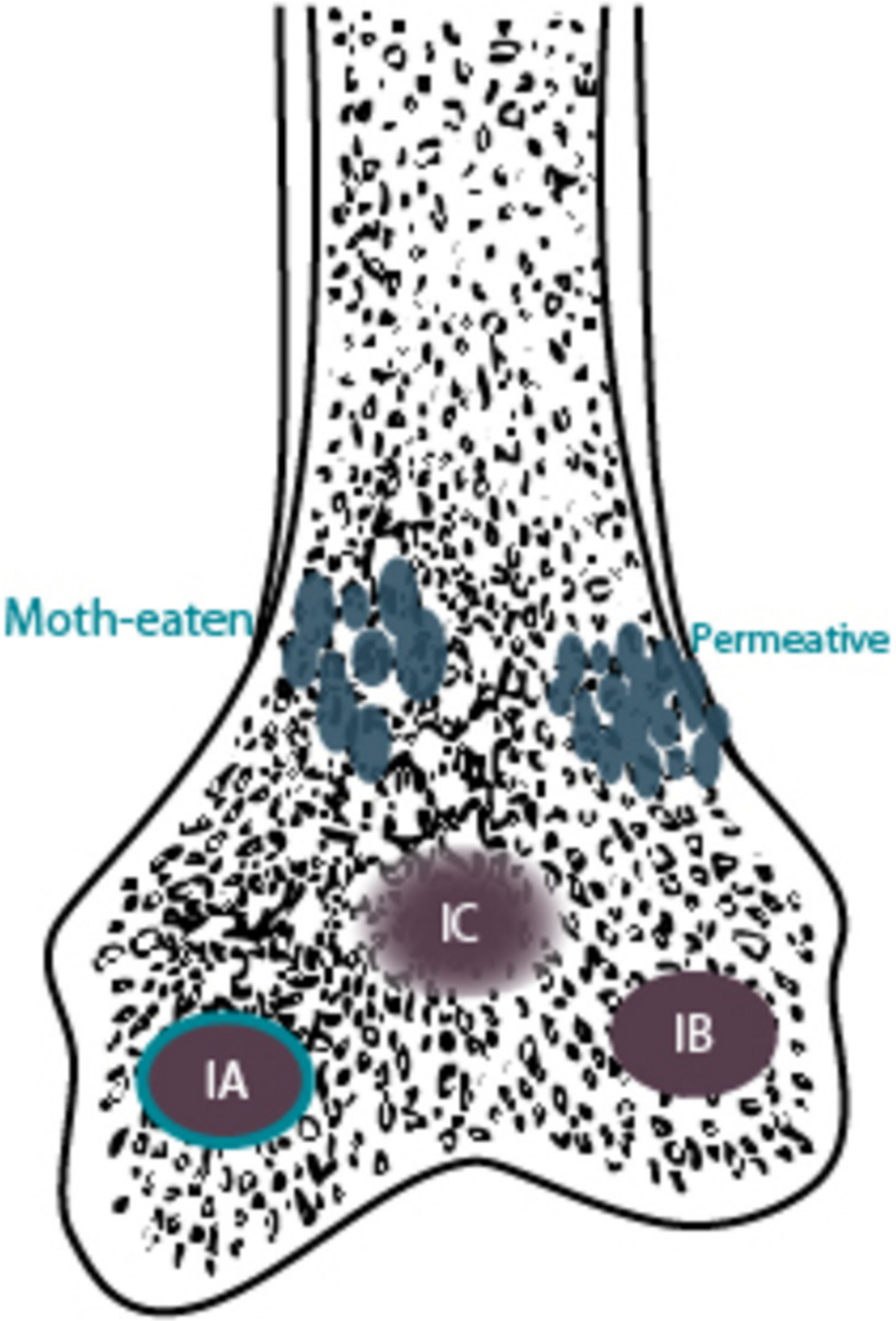
Moth-eaten
Permeative
IC
IB
IA

Fig. 7: Illustration of the different types of bone destruction, as first described by Lodwick - Type IA (geographic with sclerotic margins); Type IB (geographic without sclerotic margins); Type IC (geographic with poorly defined margins); Moth-eaten (Type II) and Permeative (Type III)
References: Radiology, Centro Hospitalar e Universitario de Coimbra, Hospital Geral - Coimbra/PT

Periosteal Response

It is usually categorized as uninterrupted or interrupted. The latter frequently suggests malignancy, but it is important to understand that nonneoplastic processes (such as osteomyelitis, bone abcesses) can cause this type of bone response. It may present as a "sunburst", lamellated or "onion-skin" pattern or as a Codman triangle (Fig. 8 on page 15). Any of these patterns can be seen with osteosarcoma or Ewing's sarcoma.

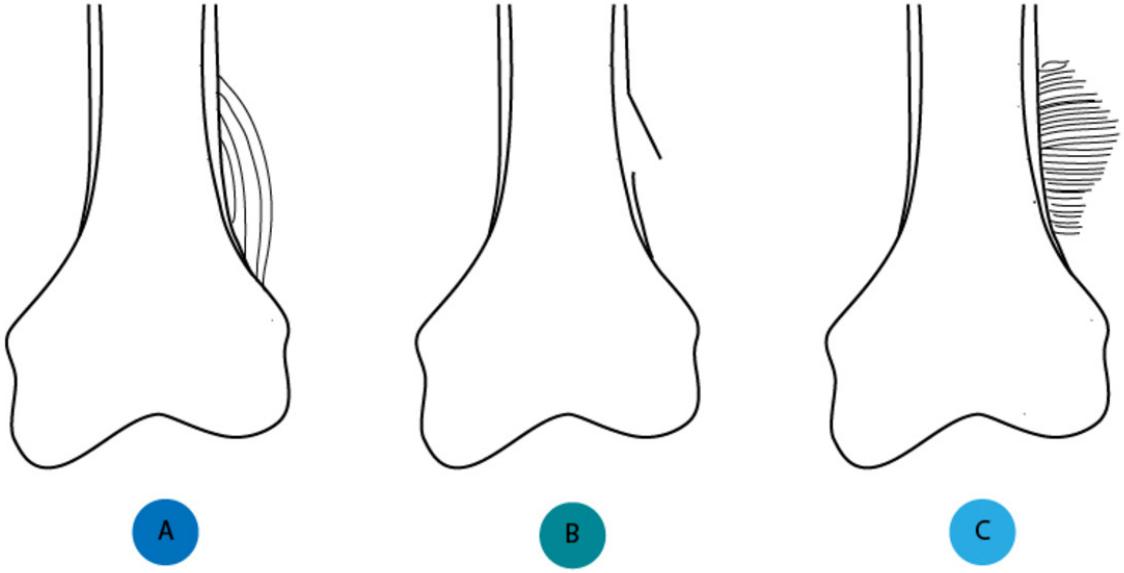

Fig. 8: Schematic representation of periosteal response. A) Lamellated or "onion skin" pattern; B) Codman triangle and C) "sunburst" pattern.
References: Radiology, Centro Hospitalar e Universitario de Coimbra, Hospital Geral - Coimbra/PT

Soft Tissue Mass or Extension

As a general rule, benign lesions usually do not exhibit extension into the surrounding soft tissues. It is frequently associated with an aggressive lesion, either neoplasic or not.

OTHER IMAGING MODALITIES

When do we perform CT, MR and scintigraphy?

CT: complementary; can be used to depict small matrix calcifications and appreciate cortical destruction; distal staging

MR: is the technique of choice for local tumor staging, when the standard radiograph shows indeterminate findings and for a specific diagnosis

Scintigraphy: documents bone metastases or lesion multiplicity

Images for this section:

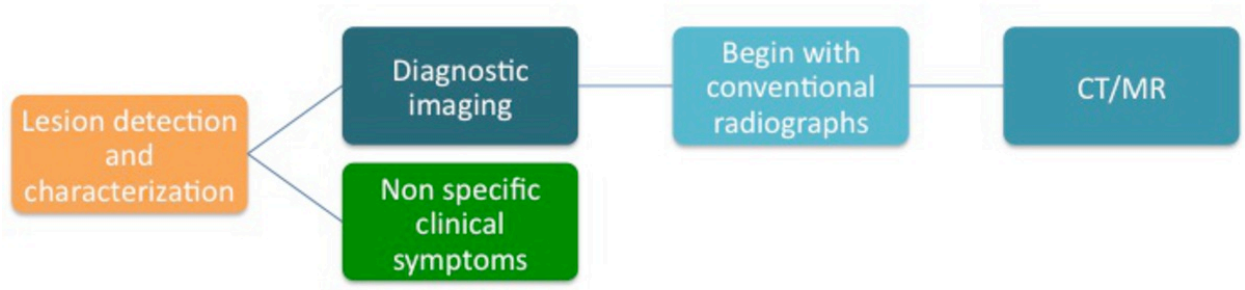

Fig. 1: Diagnostic approach of malignant bone tumors

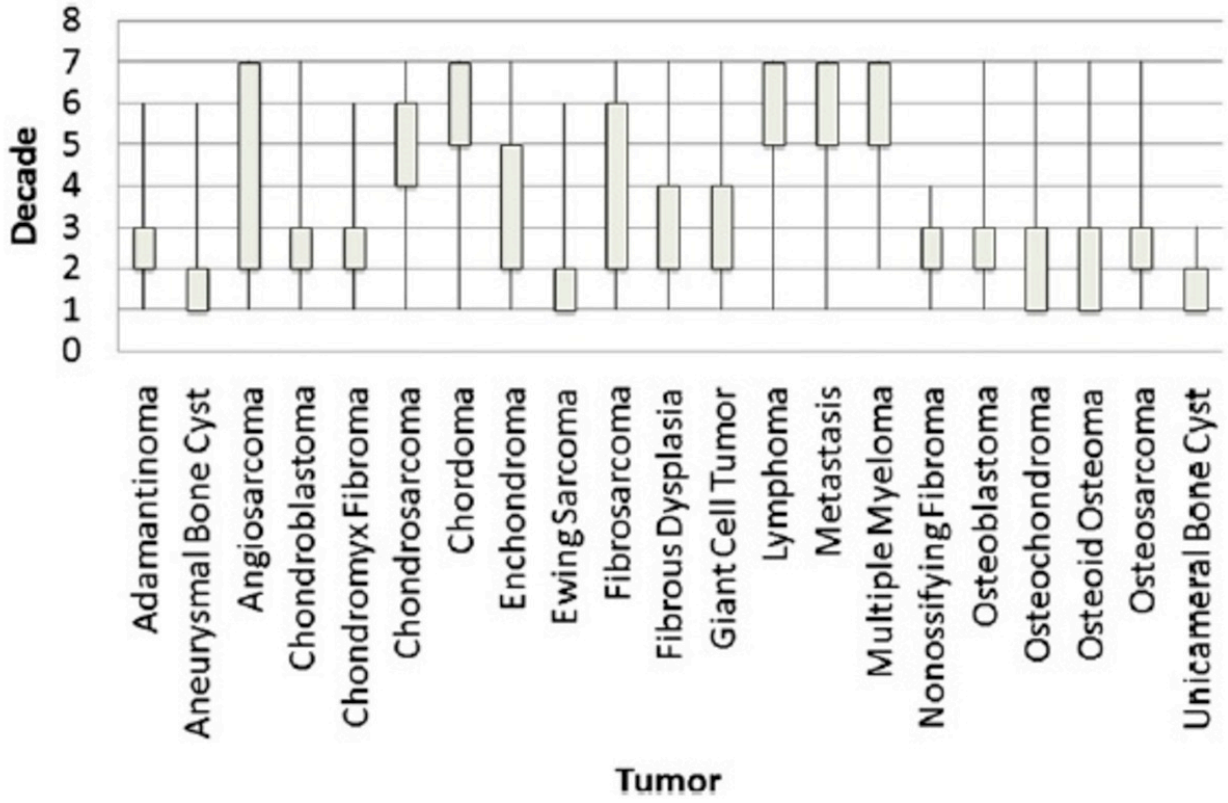

Fig. 4: Tumor distribution based on age group

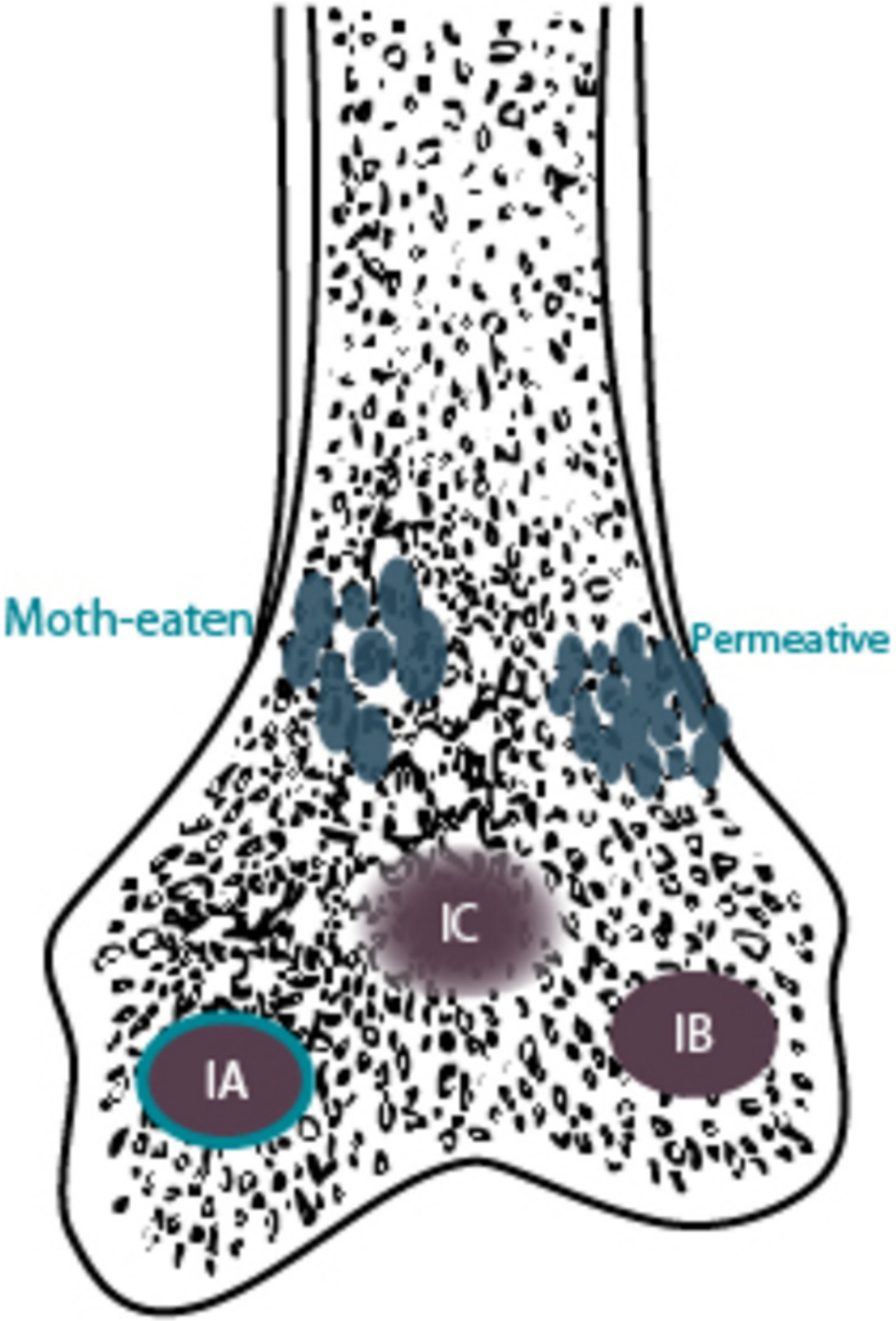
Moth-eaten
Permeative
IC
IB
IA

Fig. 7: Illustration of the different types of bone destruction, as first described by Lodwick - Type IA (geographic with sclerotic margins); Type IB (geographic without sclerotic margins); Type IC (geographic with poorly defined margins); Moth-eaten (Type II) and Permeative (Type III)

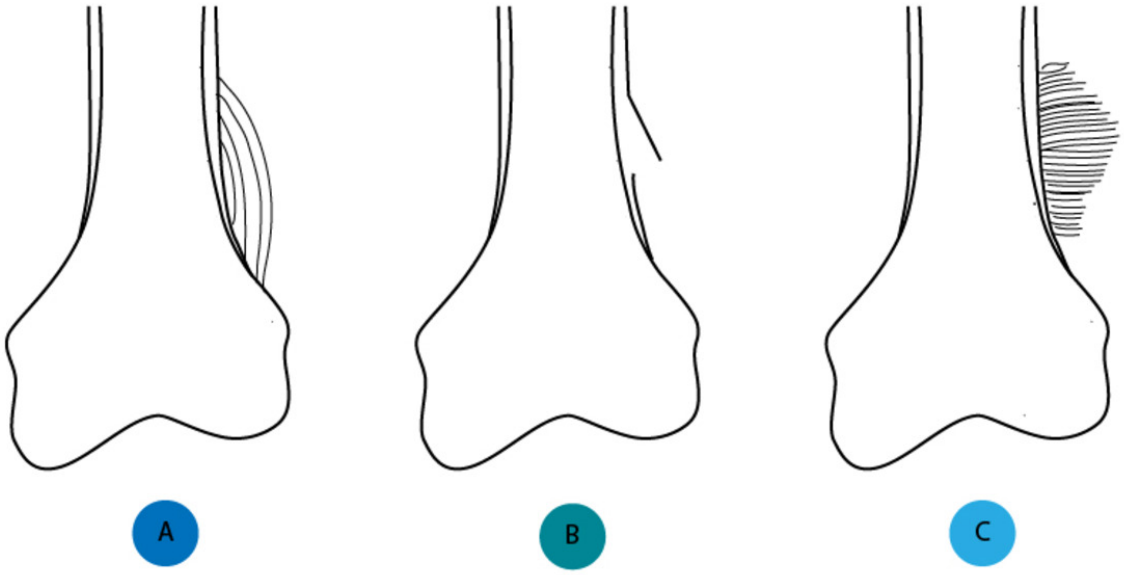

Fig. 8: Schematic representation of periosteal response. A) Lamellated or "onion skin" pattern; B) Codman triangle and C) "sunburst" pattern.

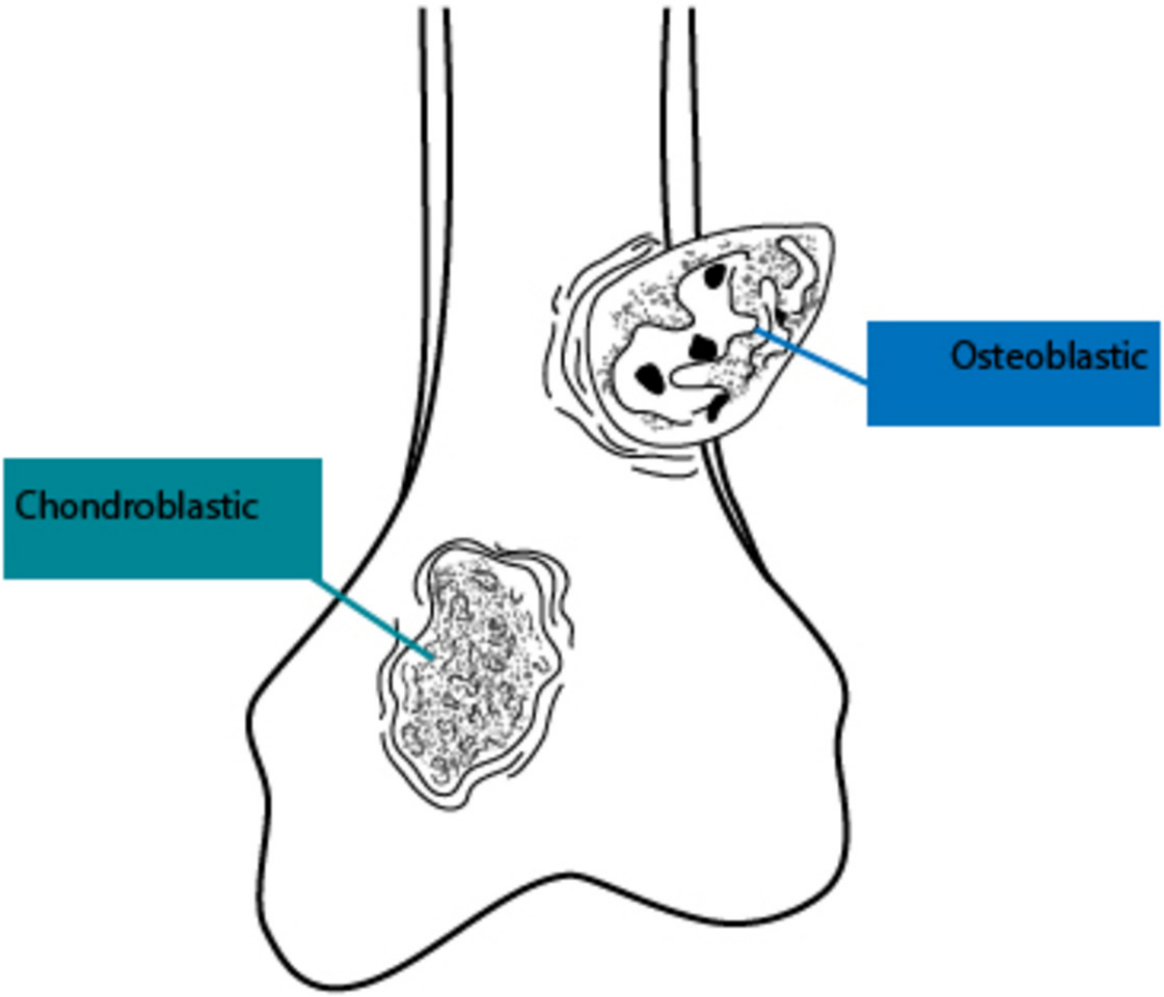

Fig. 6: Schematic representation of tumorous bone matrix.

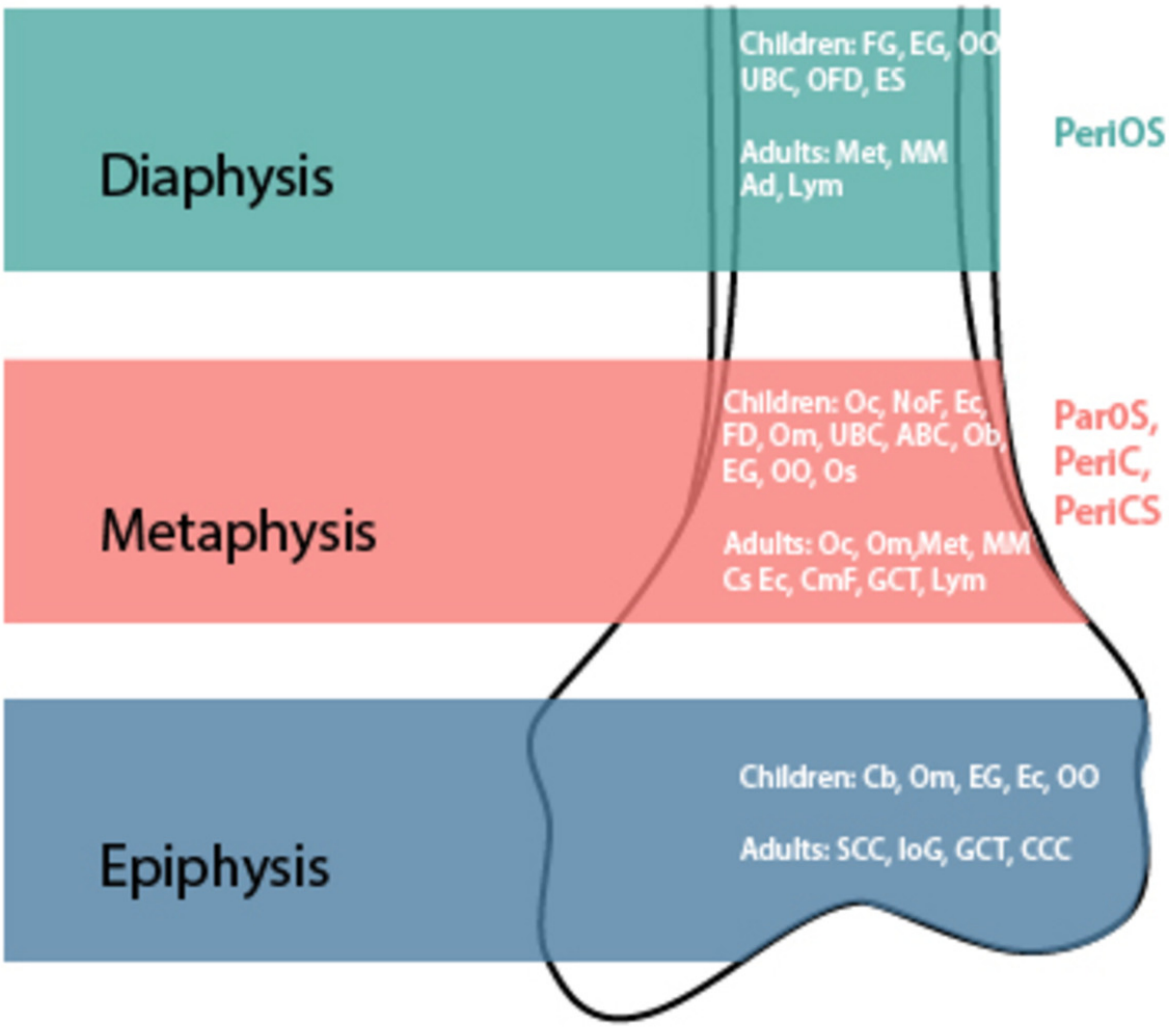

Fig. 5: Schematic representation of tumor distribution in the bone, in children and adults. ABC - aneurismal bone cyst; Ad, adamantinoma; Cb, chondroblastoma; CCC, clear cell chondrosarcoma;CmF, chondromyxoid fibroma; Cs, chondrosarcoma; Ec, enchondroma; EG, eosinophilic granuloma; ES, Ewing sarcoma; FD, fibrous dysplasia;GCT, giant cell tumor; IoG, intraosseous ganglion; Lym, lymphoma; Met, metastasis; MM, multiple myeloma; NoF, nonossifying fibroma; Ob, osteoblastoma; Oc, osteochondroma; OFD, osteofibrous dysplasia; Om,osteomyelitis; OO, osteoid osteoma; Os, osteosarcoma; ParOS, parosteal osteosarcoma; PeriC, periosteal chondroma; PeriCS, periosteal chondrosarcoma; PeriOS, periosteal osteosarcoma; SCC, subchondral cyst;UBC,unicameral bone cyst.

Imaging findings OR Procedure details

Conventional radiography is an essential aid in the diagnosis of bone lesions. In the great majority of cases, standard radiography of the site of involvement is sufficient for an accurate diagnosis.

This modality is useful in determining not only the morphology and location of the lesion, but also other aspects that suggest the malignancy: borders, type of bone destruction, periosteal response, soft tissue extension and number of lesions.

For the purpose of this educational exhibit, only the most frequent histological subtypes will be discussed.

MALIGNANT BONE TUMORS - A BRIEF REVIEW

OSTEOSARCOMA

One of the most common primary malignant bone tumors. There are several types, which exhibit distinctive clinical, imaging and histologic characteristics.

Usually, the location and histological composition determine radiographic appearance

There are three major groups: intramedullary, juxtacortical (parosteal and periosteal) or extraskeletal (soft tissue)

Conventional osteosarcoma accounts for 75% of cases, which is why we'll focus discussion on this type

Conventional Osteosarcoma

Location: metaphysis of long bones; there is a marked predilection for the knee (either distal femur or proximal tibia) and the shoulder.

Age: children and adolescents (its highest incidence is during the second decade of life)

Appearance: pure lytic/pure blastic/ most frequently it is mixed osteosclerotic and osteolytic

Periosteal reaction: the most frequent patterns seen with osteosarcoma are a Codman triangle and the "sunburst" pattern; less frequently a "onion skin" pattern can be present.

A soft tissue component is almost always present.

Fig. 9: Conventional osteosarcoma of the distal metaphysis of the right femur.
References: Radiology, Centro Hospitalar e Universitario de Coimbra, Hospital Pediátrico - Coimbra/PT


F1
F

Fig. 10: Conventional osteosarcoma of the distal metaphysis of the right femur. In this lateral view the periosteal reaction, as well as the underlying tumor matrix, becomes much more apparent.
References: Radiology, Centro Hospitalar e Universitario de Coimbra, Hospital Pediátrico - Coimbra/PT

EWING'S SARCOMA

Second most frequent primary bone tumor

May exhibit systemic symptoms, mimicking osteomyelitis

Location: variable (long bones, flat bones - ribs and pelvic bones), midshaft

Age: almost exclusively in children and adolescents

Appearance: osteolytic lesion (25% sclerotic)

Periosteal reaction: "onion skin" pattern

Soft tissue component is extremely common with these tumors.

Fig. 11: Ewing's Sarcoma of the proximal metaphysis of the left humerus. Soft tissue mass.
References: Radiology, Centro Hospitalar e Universitario de Coimbra, Hospital Pediátrico - Coimbra/PT

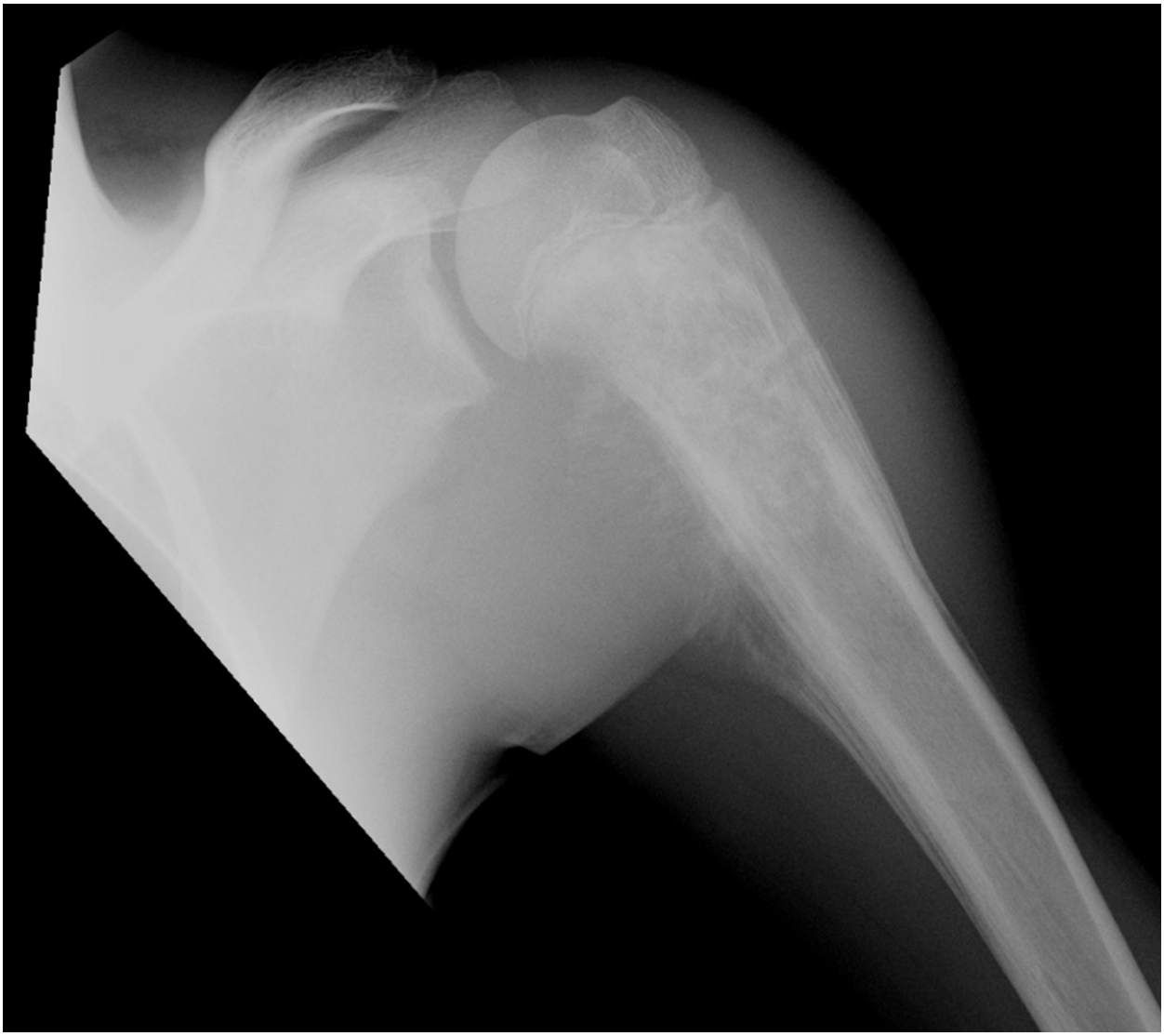

Fig. 12: Ewing's sarcoma. Shoulder AP view. Notice the periosteal "sunburst" and "onion skin" like reaction.
References: Radiology, Centro Hospitalar e Universitario de Coimbra, Hospital Pediátrico - Coimbra/PT

CHONDROSARCOMA

Mesenchymal tumor embedded in chondroid matrix. It can be subdivided regarding **origin** (primary or secondary) and **location** (central or peripheral).

a) ORIGIN:

Primary or secondary (arising from previous bone lesion: +++ enchondromatosis or multiple cartilaginous exostoses). Attention should be given to the changes in calcification pattern and clinical symptoms

Age: Primary chondrosarcoma - 30-60 years

Secondary chondrosarcoma - 20-40 years

b)LOCATION:

Central

Location: metaphysis or diaphysis, predominantly long bones (femur).

Appearance: geographic/ "moth eaten"/permeative osteolytic lesion

Peripheral

Location: scapula, iliac bone, tibia, femur, pubic bone or rib

Appearance: continuous growth of exostosis after skeletal maturity, changes in surface, internal lytic areas, erosion/destruction of adjacent bone.

Fig. 13: Low grade Chondrosarcoma. The lesion was somewhat extensive and there was doubt whether there was cortical destruction or not. This patient underwent MR and biopsy, which definitively revealed it was in fact a chondrosarcoma.
References: Radiology, Centro Hospitalar e Universitario de Coimbra, Hospital Geral - Coimbra/PT

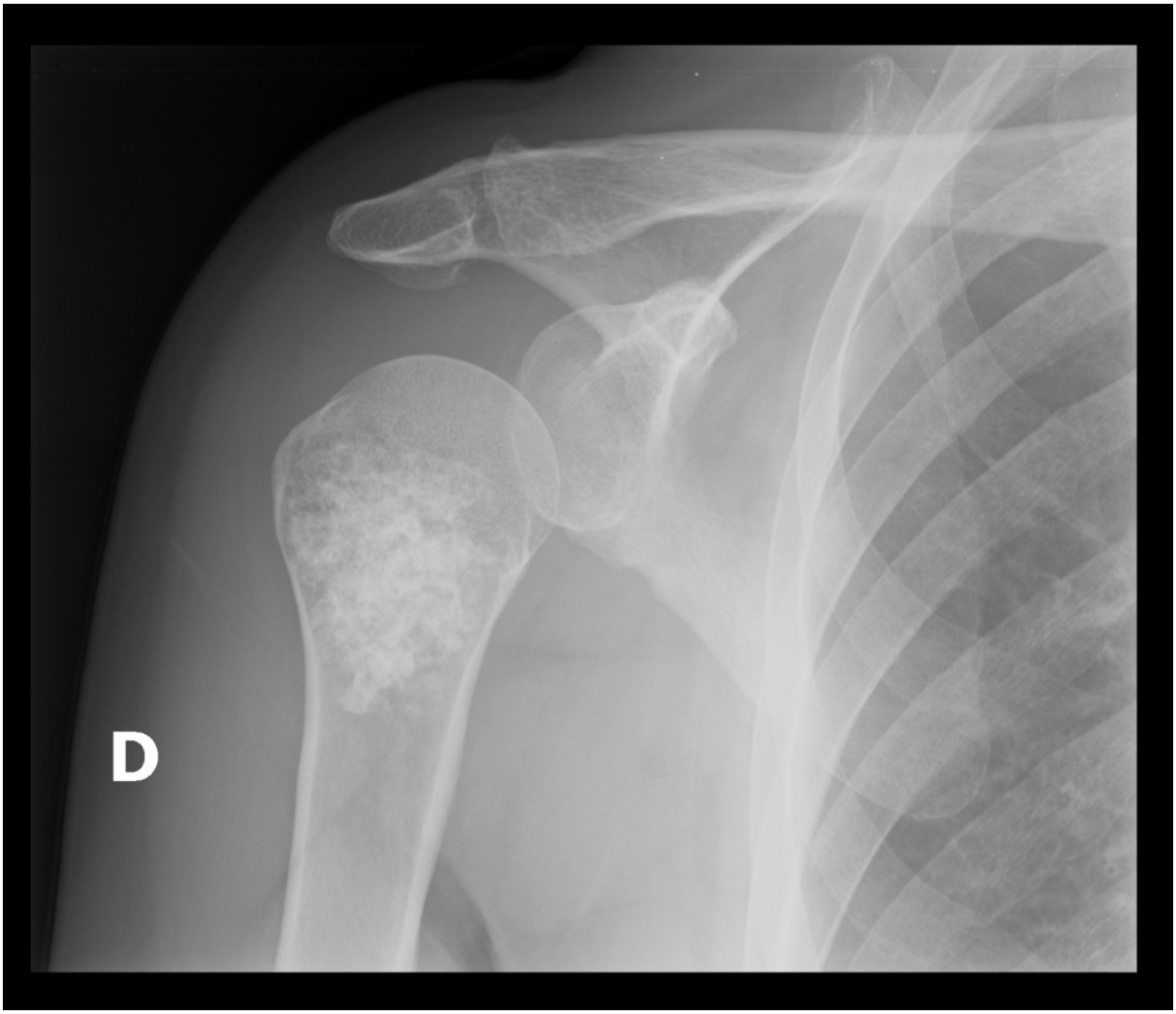

Fig. 14: Low grade Chondrosarcoma. Shoulder AP view
References: Radiology, Centro Hospitalar e Universitario de Coimbra, Hospital Geral - Coimbra/PT

PRIMARY BONE LYMPHOMA

Uncommon malignancy that accounts for < 5% all primary bone tumors

Different from secondary lymphomatous invasion of the bone: no lymphadenopathies

Symptoms: insidious and intermittent bone pain, systemic symptoms and pathological fracture.

Location: metadiaphysis of the femur, spine

Age: occurs during the second and seventh decades of life (peak from 45-75 years)

Appearance: variable; solitary, permeative osteolytic lesion with multilamellar periosteal reaction; mixed sclero-lytic lesion; "near-normal" appearance


des Pereira

Fig. 15: Primary Bone Lymphoma - note involvement of the body of the L3 vertebra
References: Radiology, Centro Hospitalar e Universitario de Coimbra, Hospital Geral - Coimbra/PT


D

Fig. 16: Primary Bone Lymphoma- Osteolytic, permeative lesion with involvement of the right femoral metaphysis.
References: Radiology, Centro Hospitalar e Universitario de Coimbra, Hospital Pediátrico - Coimbra/PT

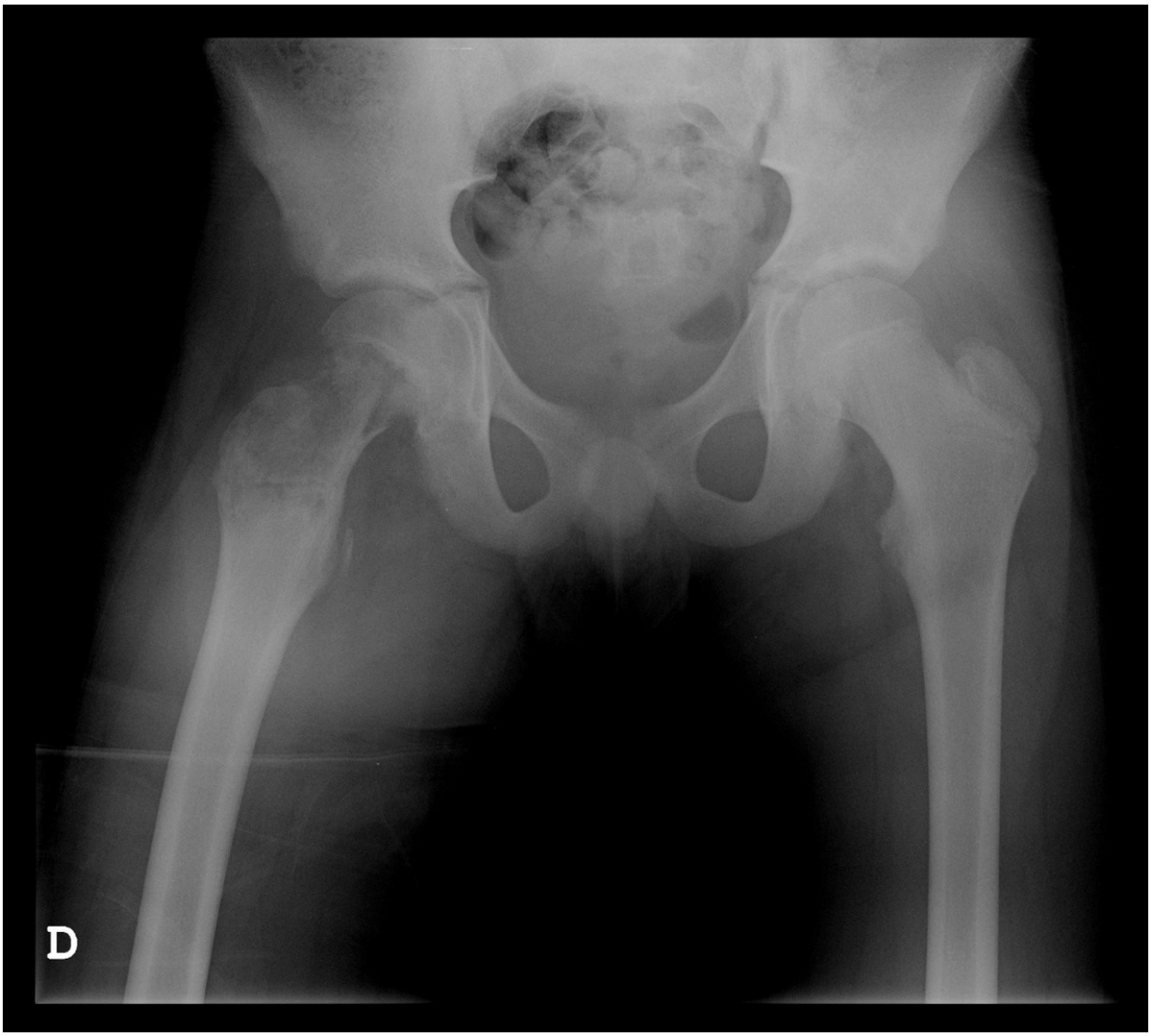

Fig. 17: Primary Bone Lymphoma - Same patient as Fig.15. In this view,the soft tissue mass, indicating an underlying aggressive lesion, becomes more apparent.
References: Radiology, Centro Hospitalar e Universitario de Coimbra, Hospital Pediátrico - Coimbra/PT

MULTIPLE MYELOMA/ PLASMACYTOMA

Multiple myeloma is the most frequent primary malignant bone tumor. When solitary, it's called a plasmacytoma. Usually it presents with widespread involvement.

Symptoms: infections, bone pain, renal insufficiency, pathological vertebral fractures with cord compression

Location: skull, spine, ribs, femora, pelvic bones

Age: elderly population (frequently between the fifth and seventh decades)

Appearance: well circumscribed osteolytic lesions ("punched-out"), "scalloping" of the inner cortical margin, diffuse loss of mineralization of the skeleton (osteopenia). Rarely, it can present with sclerosis (*sclerosing myelomatosis)*

Fig. 18: 53 year-old female patient with Multiple Myeloma. Note the characteristic "punched out" lesions, predominantly in the frontal and parietal bones.
References: Radiology, Centro Hospitalar e Universitario de Coimbra, Hospital Geral - Coimbra/PT


DTO

Fig. 19: 53 year-old female patient with Multiple Myeloma. Involvement of the right humerus, scapula and clavicle with multiple lytic lesions dispersed throughout the bones, causing cortical "scalloping".
References: Radiology, Centro Hospitalar e Universitario de Coimbra, Hospital Geral - Coimbra/PT

Fig. 20: 53 year-old female patient with Multiple Myeloma.
References: Radiology, Centro Hospitalar e Universitario de Coimbra, Hospital Geral - Coimbra/PT

CHORDOMA

Rare tumors (2-4% of all primary bone tumors), locally aggressive. These tumors originate in the embryonic notochordal remnant.

Location: sacral bone, clivus

Age: these tumors can be found at every age

Appearance: these tumors can cause bone expansion, rarefaction, trabeculation and calcification. Usually the radiographic pattern is of a lytic lesion with some degree of calcification or presence of bone sequestration.

METASTASES

Most frequent secondary bone tumors, which is why they should always be considered in the differential diagnosis of malignant bone lesions, specially in older patients.

Location: anywhere in the skeleton (mostly areas that contain red marrow, due to hematogenous spread of primary tumors)

Age: patients are usually older than 40 years

Appearance: depends on the primary tumor

Osteoblastic lesions: uterus, ovary, prostate, seminoma, neurogenic tumors

Osteolytic: kidney, thyroid, lung, colon, stomach

Although conventional radiographs can detect skeletal metastases, the best screening method is scintigraphy.

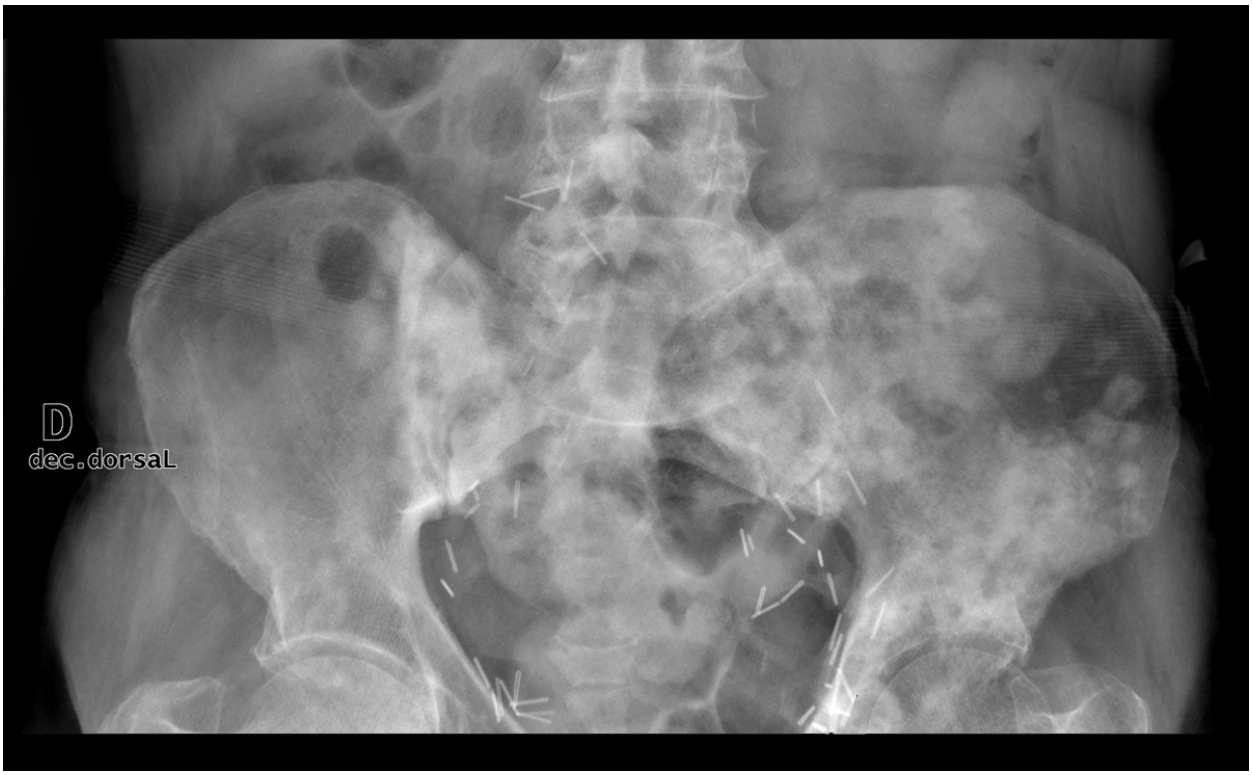

Fig. 21: 57 year-old male patient who had a metastatic bladder carcinoma. This image shows extensive blastic and lyticlesions, widespread through the pelvic bones.
References: Radiology, Centro Hospitalar e Universitario de Coimbra, Hospital Geral - Coimbra/PT

Fig. 22: 47 year-old female with breast cancer. This patient complained of knee pain and mobility impairment. There is a marked heterogeneity of the distal femur and proximal tibia, mainly due to increased sclerosis. This is highly suggestive of metastases, considering the patients clinical background.

References: Radiology, Centro Hospitalar e Universitario de Coimbra, Hospital Geral - Coimbra/PT

Fig. 23: Same patient as Fig.22. Lateral view of the left knee. In this view, there as lytic involvement of the proximal fibula, which becomes more apparent.
References: Radiology, Centro Hospitalar e Universitario de Coimbra, Hospital Geral - Coimbra/PT

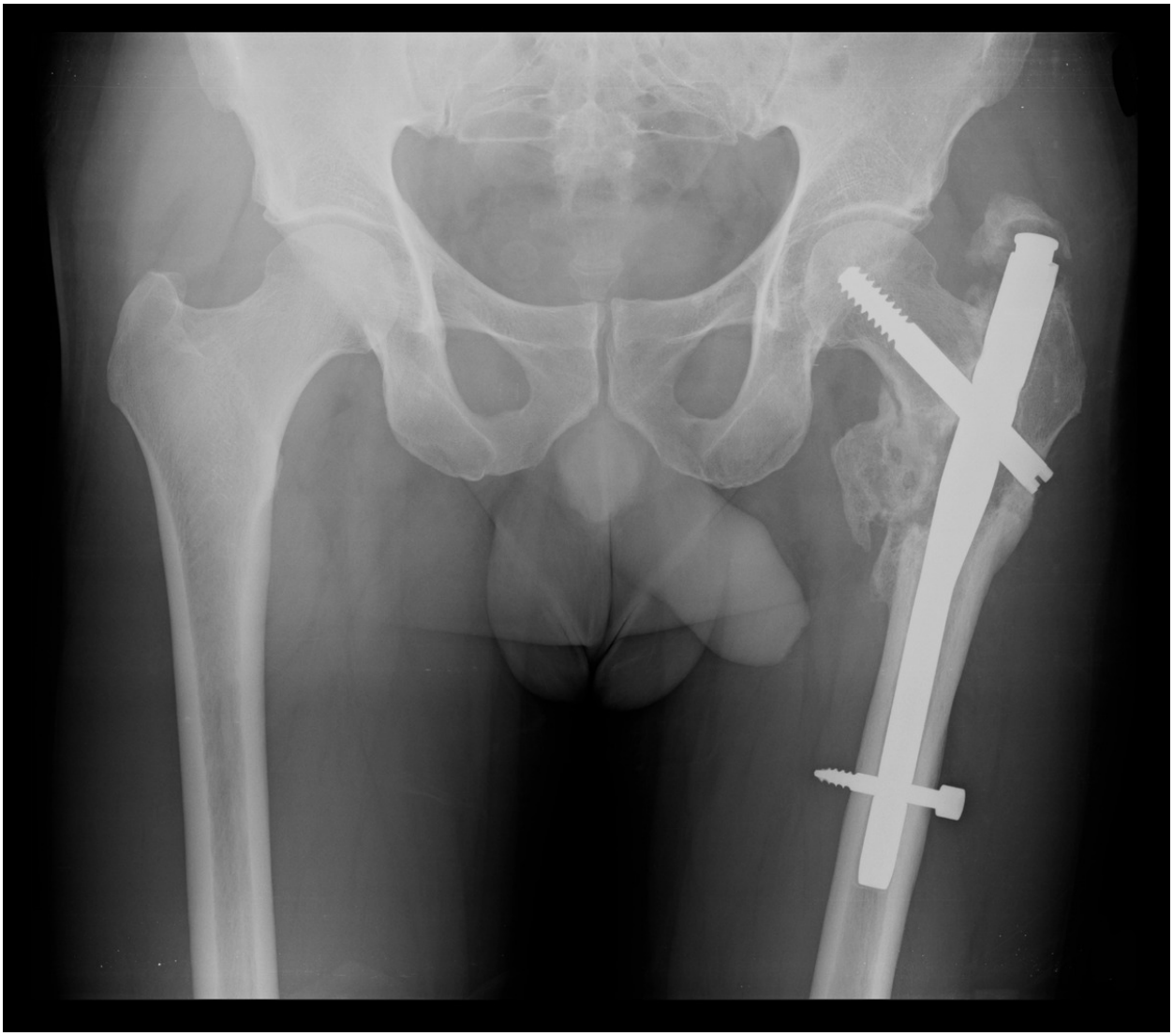

Fig. 24: 43 year-old male with a pathologic fracture of the left femur. Notice that the underlying bone is abnormal, due to the presence of a massive lytic lesion secondary to a renal carninoma.
References: Radiology, Centro Hospitalar e Universitario de Coimbra, Hospital Geral - Coimbra/PT

Conclusion

The diagnosis of malignant bone tumors isn't an easy task for most radiologists. These tumors are frequently discovered by coincidence, on standard radiography, after minor trauma.

The purpose of this poster was to provide a pattern approach for the diagnosis, while reviewing some of the most important imaging findings of malignant bone tumors in conventional radiography.

Despite a vast array of imaging modalities, such as CT and MR, the diagnosis of malignant bone lesions is still very dependent on conventional radiography, which should be considered the first step in the diagnostic approach.

One must keep in mind that histology is the gold standard for definitive characterization of a malignant bone tumor. Nevertheless, the combination of information regarding age, location, multiplicity and features on standard radiographs can help and narrow the diagnosis.

References

Perre, S., Vanhoenaker, F.M., Geniets, C., Van Dyck, P, Gielen, J., Samson, I., Parizel, P., Imaging of Malignant Bone Tumors, *JBR-BTR*, 2006, 89: 275-280

Stacy, G., Mahal, R., Peabody, T., Staging of Bone Tumors: a review with Illustrative Examples, *AJR* 2006; 186:967-976

Miller, T., Bone Tumors and Tumor-like Conditions: analysis with Conventional Radiography, *Radiology*, Volume 246: Number 3-March 2008

Nichols, R., Dixon, L., Radiographic analysis os solitary bone lesions, *Radiol Clin N Am* 49, 2011, 1095-1114

Personal Information